



26th Annual General Pediatric Review & Self-Assessment

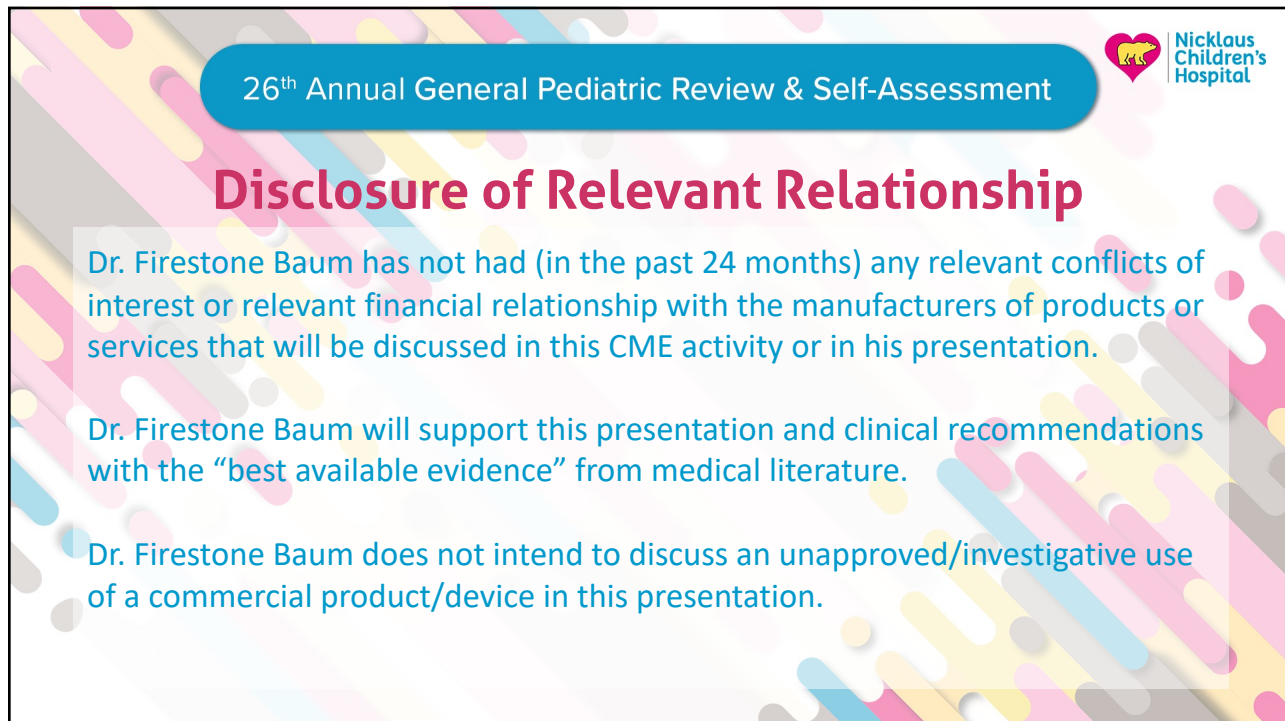


GASTROENTEROLOGY


Carrie Firestone Baum, MD

Attending, Pediatric Gastroenterology
Nicklaus Children's Pediatric Specialists
Nicklaus Children's Hospital
Miami, Florida

1



26th Annual General Pediatric Review & Self-Assessment



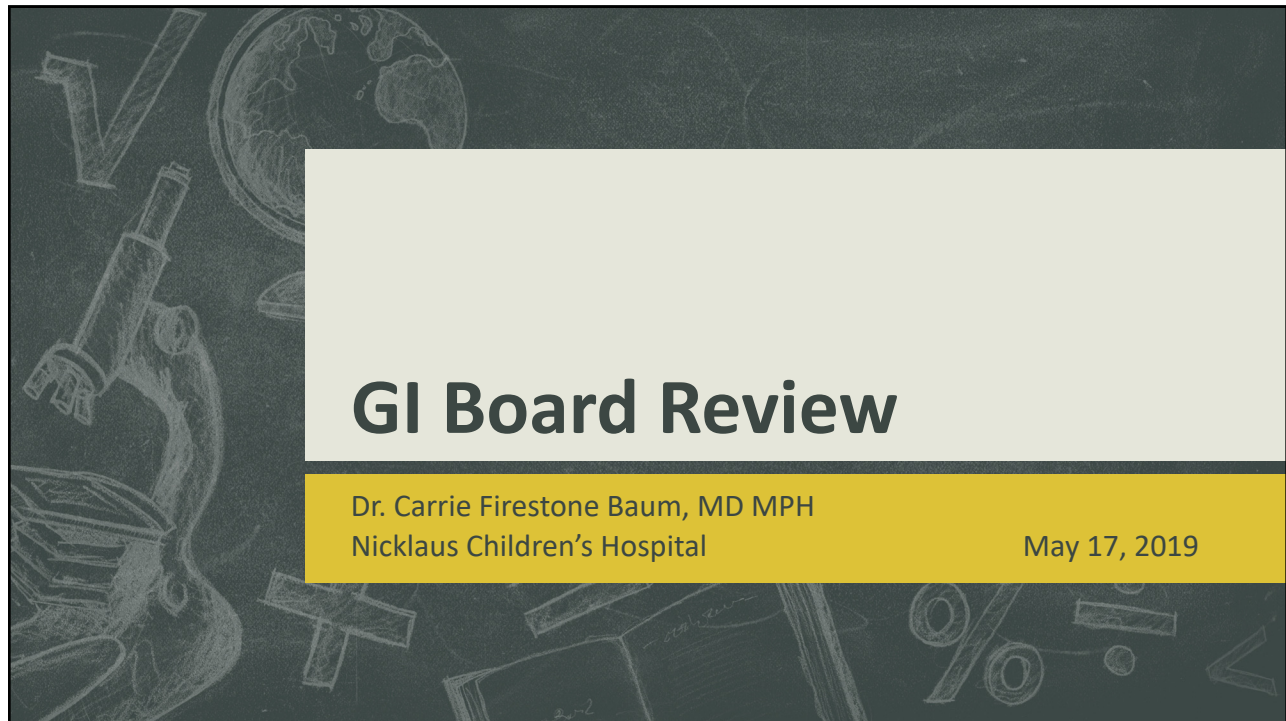
Disclosure of Relevant Relationship

Dr. Firestone Baum has not had (in the past 24 months) any relevant conflicts of interest or relevant financial relationship with the manufacturers of products or services that will be discussed in this CME activity or in his presentation.

Dr. Firestone Baum will support this presentation and clinical recommendations with the “best available evidence” from medical literature.

Dr. Firestone Baum does not intend to discuss an unapproved/investigative use of a commercial product/device in this presentation.

2



GI Board Review

Dr. Carrie Firestone Baum, MD MPH
Nicklaus Children's Hospital

May 17, 2019

4

Case 1

A 17 year old member of the track team comes in with epigastric discomfort and nausea. The big meet is tomorrow and he has been training hard for his last chance to win the medal in his event. He has no significant past medical history other than mild exercise induced asthma and uses an inhaler as he needs. He also uses ibuprofen for muscle pain when training.

What is your diagnosis?

- a) Atypical asthma
- b) Performance anxiety
- c) Intestinal parasite
- d) NSAID complication

5

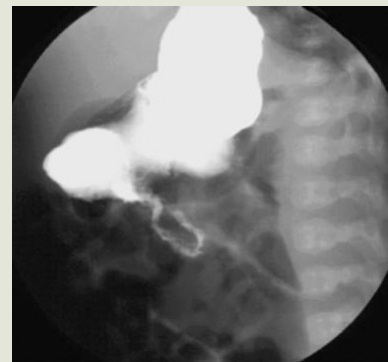NSAID induced injury

- Inhibits COX-1 which has activity in the gastric mucosa thereby decreasing prostaglandin synthesis
- Leads to decreased bicarbonate and mucus production which impairs barrier protection of mucosa
- reduce gastric mucosal blood flow and interference with the repair of superficial injury
- Leads to: dyspepsia, epigastric pain, cramping, nausea, vomiting, gastritis, ulcers
- Treatment: H2 blocker or PPI

7

Abdominal Pain-Volvulus

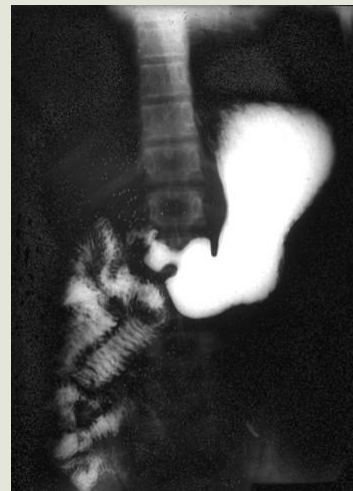- Abnormal fixation of bowel mesentery during fetal development
- Most occur in utero or early infancy
- Sudden onset of abdominal pain and **bilious** emesis
- Ischemia and necrosis
- Diagnosed by UGI series
- If barium enema: malposition of cecum



8

Malrotation

- Usually present at an early age but can present later in life
- 75% present during the first month of life, 15% in the first year
- 1/6000 live births
- **Bilious** emesis
- With or without volvulus



9

Acute Pancreatitis

- Reversible process
- More prevalent than chronic
- Need 2 of the 3 for diagnosis
 1. abdominal pain suggestive of or compatible with: acute onset in the epigastric region
 2. serum amylase and/or lipase activity at least 3 times greater than that upper limit of normal
 3. imaging compatible with acute pancreatitis (be careful)

10

Chronic Pancreatitis

- Recurrent episodes of acute pancreatitis with consequences
- Abdominal pain – epigastric, radiate to back, relieved by sitting up/leaning forward, worse post-prandial and after fatty meals
- Nausea and vomiting
- Obstructive jaundice
- Abnormal liver tests
- Growth failure/malnutrition
- Glucose intolerance
- Pancreatic pseudocysts

11

Differential of Chronic Pancreatitis

- Cystic Fibrosis
- Hereditary Pancreatitis-PRSS1, SPINK1, CFTR
- Gallstone Pancreatitis
- Drug/Toxin induced Pancreatitis
- Anatomical anomalies—pancreas divisum
- metabolic disorders
- Autoimmune
- hyperlipidemia

12

Case 2

A 14 month old female presents with history of “severe spells of crying” over the last 20 hours. Her parents describe intermittent episodes of “suddenly crying out in pain” associated with flexion of her knees “like she is trying to have a bowel movement.” She has vomited twice, and her appetite is decreased. Prior to the onset of symptoms she appeared well and fed normally. On exam, she appears lethargic but becomes irritable when disturbed. Her abdomen is slightly tender and distended. Stools are Heme-positive.

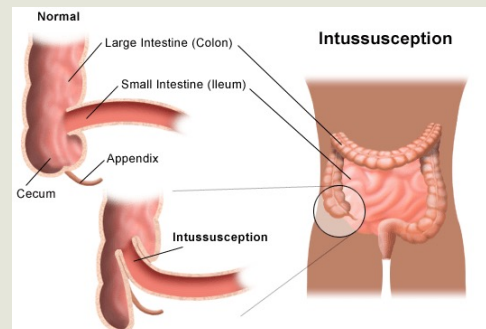
Which represents the most likely finding upon further evaluation of the patient?

- A) A “coil spring” appearance in the proximal transverse colon on barium enema
- B) A thickened pylorus on ultrasound
- C) Distended bowel with air fluid levels on cross table lateral radiograph
- D) A distended and gas filled stomach and proximal duodenum
- E) Malposition of the cecum on barium enema

13

Intussusception

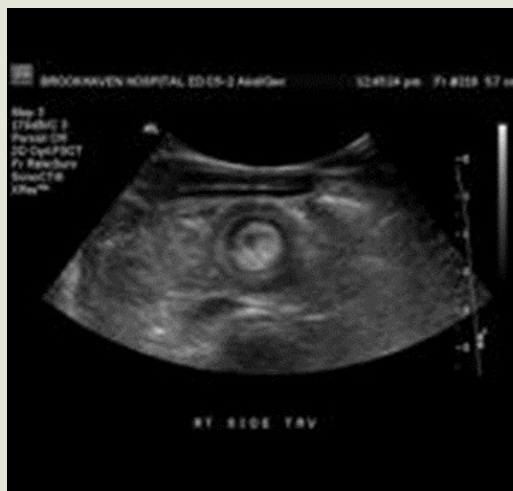- Most common cause of intestinal obstruction between 3 months-6 yrs of age
- Sudden onset of severe, paroxysmal colicky pain that recurs at frequent intervals
- Well in between episodes of pain, can become weak and lethargic
- 70-90% reduce



15

Intussusception

- Males > females
- Currant jelly stools
- Air enema: diagnostic and therapeutic



16

Abdominal pain-Blunt trauma

- Pancreatic pseudocyst
- Pancreatitis
- Duodenal Hematoma
 - Handlebar, seatbelts, abuse
 - NG tube relieves distention
 - US can see mass from hematoma, UGI

17

Case 3

11 year girl comes to see you for recurrent periumbilical pain for the last 9 months. It is worse in the morning, especially on school days. There is no vomiting or weight loss but she does frequently have non-bloody diarrhea with resolution of the pain. Her exam is benign and stool is guaiac negative.

Which of the following is your preferred working diagnosis?

- a) Celiac Disease
- b) Crohn Disease
- c) irritable bowel syndrome
- d) ulcerative colitis

18

Case 4

Her symptoms persist so you plan an evaluation that should include all of the following EXCEPT:

- a) celiac serology
- b) lactose breath test
- c) abdominal CT scan
- d) stool for ova and parasites

20

Case 5

Reasonable interventions for this patient would not include:

- a) Cognitive behavioral therapy
- b) Dietary manipulation
- c) Trial of low dose Tri-cyclic antidepressants
- d) Empiric therapy for *Helicobacter pylori*
- e) Symptom-based therapy

22

Irritable Bowel Syndrome

Diagnostic Criteria:

- Pain or Discomfort in the belly
- Associated with the need to defecate
- Need 2 of the following 3:
 1. Pain is improved with defecation
 2. There is a change in frequency in stool
 3. There is a change in consistency in stool

Needs to be present at least 1 time per week over the preceding 2 months without any evidence of any anatomic, pathologic or neoplastic process

24

Functional GI Disorders:

Treatment

- Education and reassurance
- Proper nutrition/food avoidance- Some studies up to 50% improve with fiber
- Counseling/Cognitive-Behavior
- Medications: Antispasmodic, Anti-diarrheal, Probiotics ,Tricyclic antidepressants, Serotonin receptor agents

25

Abdominal Mass Differential

- Wilms tumor
- Hepatoblastoma
- RCC
- Neuroblastoma
- Rhabdomyosarcoma
- Intussusception
- lymphoma

26

Age related differential of vomiting

Newborn:

- atresia-bilious depending on level of obstruction
- Meconium ileus-bilious; associated with CF
- Hirschsprung disease-bilious or nonbilious
- NEC
- Inborn errors of metabolism; may have acidosis or hypoglycemia

27

Age related differential of vomiting

0-3 months:

- Pyloric stenosis: non bilious
- Malrotation: bilious
- Inborn errors of metabolism: bilious or non bilious
- Milk/soy protein intolerance
- GE reflux

28

Age related differential of vomiting

3-12 months

- Gastroenteritis
- Intussusception
- Increased ICP
- Eosinophilic esophagitis
- GER

29

Case 6

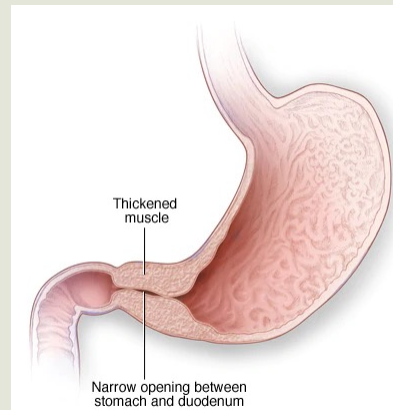
A concerned 22 year old first time mom brings in her 6 week old “vomiter”. After every feed her son “vomits the whole thing”. You note the child is slightly above birth weight and the mother states he seems to be urinating less. Which of the following studies would help you make the diagnosis?

- a) A metabolic evaluation
- b) Stat head CT scan
- c) Upper endoscopy by your local Pediatric GI
- d) Abdominal sonography

30

Pyloric Stenosis

- Projectile, non-bilious emesis
- Most common cause of gastric outlet obstruction in neonates
- M>F \square
- “olive”
- pyloric sonogram
- Hypochloremic metabolic alkalosis
- Surgery after electrolyte repletion



32

Case 7

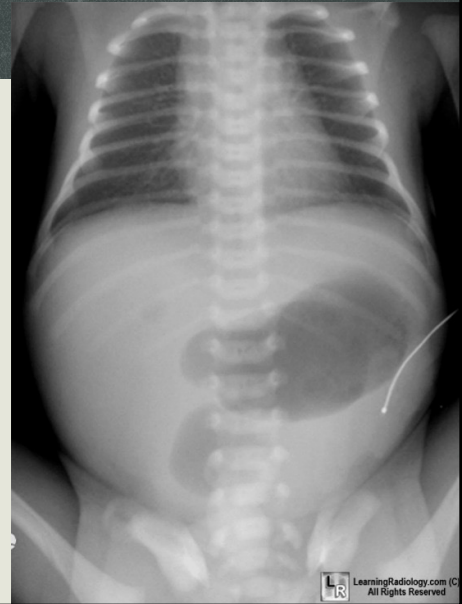
A 45 year old post-partum mother comes to see you with her Trisomy 21 infant who was just sent home from the hospital “vomiting”. The child is just at birth weight. You send her to the ED and a series of radiographs do not show an obstructive pattern. Rather, there are only two pockets of air in the epigastric region. You are again the star as you diagnose which of the following?

- a) Vulnerable child syndrome
- b) Celiac disease
- c) Milk protein allergy
- d) Duodenal atresia

33

Duodenal Atresia

- Double-bubble sign
- 1:4,500 newborns
- 2-5% Trisomy 21
- Assoc with obstructive processes i.e. annular pancreas
- Also found in fetal alcohol syndrome



35

Cyclic Vomiting

- Episodes of intense nausea and vomiting lasting hours to days
- Rule out organic causes:
 - CBC, CMP, acucheck
 - metabolic work up: lactate, ammonia, PAA, plasma acylcarnitine, UOA
 - UGI with SBFT
 - Consider brain imaging
- Family history of migraines common

36

Regurgitation

- Backward movement of stomach contents up the esophagus into the mouth and often out of the mouth
- Common in infants
- “spitting up”
- Physiologic; immature LES, delay in gastric emptying
- Doesn’t respond to acid medications

37

Rumination syndrome

- Chronic motility disorder characterized by effortless regurgitation of most meals following consumption, due to the involuntary contraction of the muscles around the abdomen.
- There is no retching, nausea, heartburn, odor, or abdominal pain associated with the regurgitation, as there is with typical vomiting.
- Does not respond to acid medications
- Does not occur during sleep
- CBT is the mainstay of treatment

38

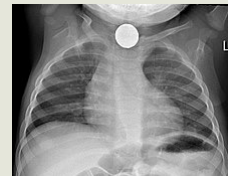Evaluation of GE reflux

- UGI NOT useful
- pH monitoring: records numbers and duration of reflux episodes
- EGD with biopsy to evaluate for esophagitis as well as other conditions like Crohn's or Eosinophilic esophagitis

39

Ingestions

- Foreign bodies present with dysphagia and possibly poor handling of secretions
- Not all foreign bodies are seen on plain film—may need barium
- Endoscopic removal timeframe depends on ingestion
- Alkali ingestions may burn esophagus and not the mouth
- Alkali ingestions are more caustic than acidic ingestions
- Risk of esophageal perforation, stricture and long term increase in cancer risk



40

Case 8

A 5 yr old girl was tx with amoxicillin for OM. One week later, she developed abdominal pain, and has been passing 6 stools daily that contain blood and mucus. PE has Temp of 101, abdominal distention and diffuse abdominal tenderness.

Among the following, the most appropriate initial diagnostic study to perform is:

- a) Barium enema
- b) Colonoscopy
- c) Clostridium difficile toxin evaluation
- d) Stool for O & P
- e) Stool for rotavirus

41

Diarrhea-infectious

- Viral-less than one week
- Rotavirus: most common cause of viral diarrheal disease in infants and toddlers
- Bacterial—sick, blood
- Salmonella, Shigella, Yersinia, Campylobacter, E Coli
- Parasitic—persistent
- **C. Difficile: After antibiotics/hospitalization
- Check for toxin A and B
- Colonization not pathogen in neonates
- Anti-diarrheals are NOT recommended in kids

43

Food Borne Diarrheal illnesses

- Fecal-oral
- Salmonella and Campylobacter- Poultry, unpasteurized milk
- Yersinia enterocolitica-Pork
- Norwalk virus- Raw seafood
- Giardia lamblia, Campylobacter, Cryptosporidium-Water

44

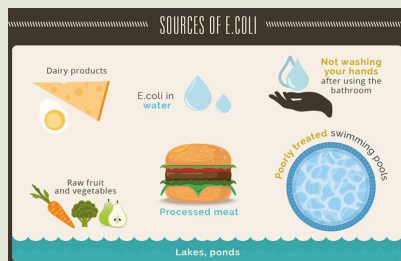
E.Coli infection

Enterotoxigenic E.coli

- Severe diarrhea
- Abdominal cramping
- Usually self limited

Enteropathogenic E.coli

- Acute and chronic diarrhea, nonbloody
- Fever
- vomiting



45

E.Coli O157:H7

- Produces shiga toxin
 - Associated with undercooked meat, fresh produce, water supplies
 - Effects the colon
 - Mild diarrhea to severe hemorrhagic colitis.
 - HUS: hemolytic anemia, thrombocytopenia and renal dysfunction
- **associated with anti-diarrheal and antibiotic use**

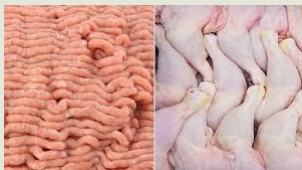

46

Salmonella vs. Shigella

Salmonella (non-typhoidal)

- Invades distal ileum
- 2-3 days of fever
- Abdominal pain
- Bloody diarrhea



Shigella

- Multiplies in the small intestine, invades and proliferates, produces toxins that have secretory and cytotoxic effects
- Ulcerations
- Mucoïd and bloody diarrhea



47

Non infectious diarrhea-Toddler's diarrhea

- Clinically well
- Good wt gain and growth-normal growth and development
- Stool: Frequent, undigested food
- High osmolarity fluids: juice, gatorade, powerade, ice tea, etc.



48

Diarrhea in infants-milk protein intolerance

- Colitis in a breast fed infant is likely due to allergens in mom's diet
- Most commonly dairy-cow's milk
- 50% of cow's milk allergic will have soy protein intolerance as well
- Strict elimination
- Can take weeks to months to resolve



49

Case 9

The parents of a 10 day old male are concerned that he is constipated. He was born at term with an uncomplicated stay. He had meconium at 29 hours of age. Since discharge he has had 2 more stools. He is breast fed and weighs 4 oz above birth weight. Abdomen is distended on exam. He vomits bilious material during the abdominal exam. Following a rectal exam he has an explosive stool.

Which of the following is considered the most accurate method to establish a definitive diagnosis in this patient?

- a) Rectal biopsy
- b) Abdominal radiograph
- c) Contrast enema
- d) Anorectal manometry
- e) Results of rectal exam

50

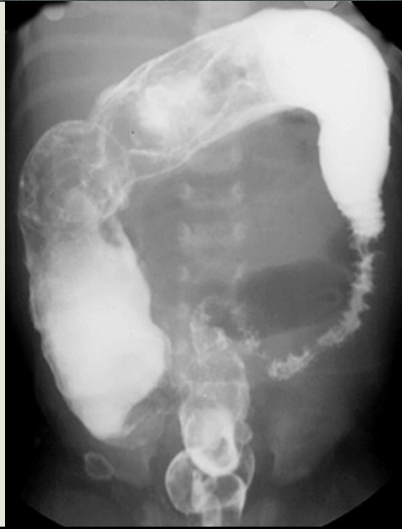
Constipation-Hirschsprung Disease

- 1/5000 births
- **Absence** of enteric ganglionic neurons that begin at the anus and then extend proximally
- Increased association with **Down syndrome**
- Evaluate any term infant that **does not pass meconium within 48 hours of birth**
- **Explosive stool on DRE- increased tone**

52

HIRSCHSPRUNG

- Failure to thrive
- Abdominal distension
- Vomiting/obstructive picture
- **Barium enema** for transition zone
- **Suction rectal biopsy or full thickness**
- Potential complications:
 - Perforation esp. cecal
 - Hypoproteinemia due to PLE
 - Enterocolitis/sepsis
 - Death



53

Case 10

A six year old is brought to you for diarrhea. Child stools multiple times during the day—seems to be all day. Often there is stool in the underwear. Your exam is notable for a tympanitic abdomen and LLQ mass.

What is your diagnosis?

- a) Neuroblastoma
- b) Giardiasis
- c) Lactose intolerance
- d) Fecal overflow incontinence

54


Simple Constipation

- Majority is due to functional or behavioral problem
- Small percentage of children present with constipation have an organic cause
- Some breast-fed babies will stool 1/5-10 days, even longer
- Functional fecal retention is the most common nonorganic cause
- **HINT: Rectal examination:** Rectal ampulla is full

56

Constipation treatment

- Stimulant laxatives— Senna, bisacodyl (need a colon)
- Stool softeners/osmotics – PEG, Lactulose, ducosate
- Lubricants-Mineral oil



57

Case 11

What is the most common cause of rectal prolapse?

- a) Constipation
- b) Cystic Fibrosis
- c) Connective tissue disorder
- d) Parasitic infection

58

Case 12

A 3,200 gm newborn is noted to be jaundiced on postnatal day #10. Total Bili is 9.0 with a direct Bili of 0.8 mg/dl. Hct is 48%. Baby and mom are blood type O, Rh+. Baby is breast fed exclusively.

The most likely explanation for high Bili is:

- a) Biliary atresia
- b) "breast milk" jaundice
- c) Choledochal cyst
- d) Hypothyroidism
- e) Neonatal hepatitis

60

Jaundice

- Jaundice in first 24 hours of life is always pathologic
- ABO incompatibility is the most common cause of isoimmune disease in the newborn
- Jaundice may persist for 2-3 weeks, if longer, investigate
- Know fractionation!

62

Unconjugated Hyperbilirubinemia

- Physiologic – exaggerated by hemolysis or hematoma
 - Peaks at day 4 and may last 2 weeks
- Breast feeding-typically due to not consuming enough, poor milk supply
- Breast Milk (late onset) –around day 7, due to increased enterohepatic circulation of bilirubin
- Crigler-Najjar syndrome I & II
- Hypothyroid
- Intestinal obstruction

63

Case 13

A breast-fed infant is found to have an indirect bilirubin level of 15 mg/dL on day 15 of life. Of the following, the statement which most correctly describes hyperbilirubinemia as a result of ingestion of breast milk is?

- a) Excess bilirubin production is the primary etiologic factor.
- b) A bilirubin level >10 mg-dL on the first day of life is typical
- c) The condition will resolve spontaneously
- d) Affected infants are at risk of kernicterus
- e) The bilirubin is transmitted in the breast milk.

64

Case 14

A 3 wk old girl has fever and vomiting. PE include bulging fontanelle and hepatomegaly. The pt had jaundice and vomiting during the 1st wk after birth. She has been breast-fed. What is the most likely Dx?

- a) Fructose aldolase deficiency
- b) Fructose 1,6 diphosphatase deficiency
- c) Glycogen Storage Disease type 1
- d) Neonatal adrenoleukodystrophy
- e) Galactosemia

66

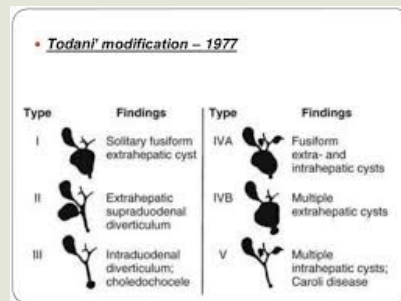
Galactosemia

- Anorexia/vomiting
- Weight loss/poor weight gain
- Cataracts
- Ascites
- Sepsis: ecoli
- Jaundice
- Galactose-1-phosphate uridyl activity
- Treatment: soy formula

68

Direct Hyperbilirubinemia-Extrahepatic

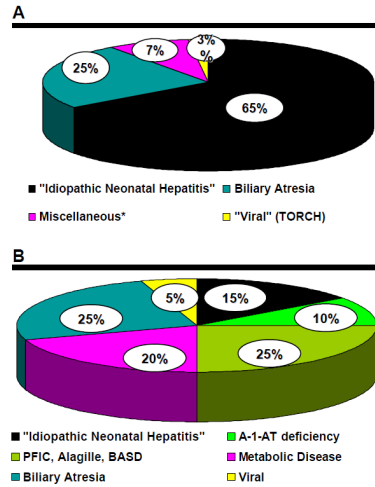
- 1.*** Extrahepatic Biliary Atresia
2. ***Choledochal Cyst
3. Choledocholithiasis
4. Extrinsic bile duct compression



69

Direct Hyperbilirubinemia-Intrahepatic

1. Metabolic
2. Familial intrahepatic cholestasis
3. Infectious
4. Anatomic – Paucity of intrahepatic bile ducts
5. Misc – TPN, Neonatal Lupus



70

Extrahepatic Biliary Atresia

- 1/3 of cases of neonatal cholestasis
- Incidence: 1: 15000 (400-500 INFANTS PER YEAR)
- Females >>>males
- Is a dynamic and progressive panductular sclerotic process
- Jaundice; persistent 3-5 weeks after birth

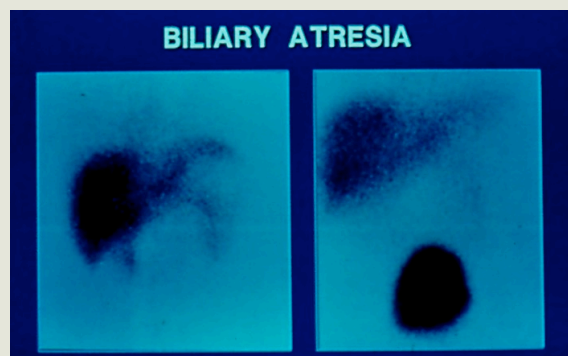
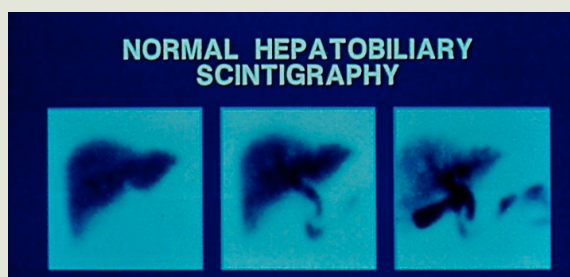
71

Biliary Atresia

- Liver enzymes mildly elevated but up to 5X normal (usually between 150-300)
- Direct hyperbilirubinemia
- Alkaline phosphatase markedly elevated
- Hepatosplenomegaly
- Acholic Stools
- Abdominal distention
- Failure to thrive
- HIDA scan
- Liver Biopsy-timing is key
- Cholangiogram

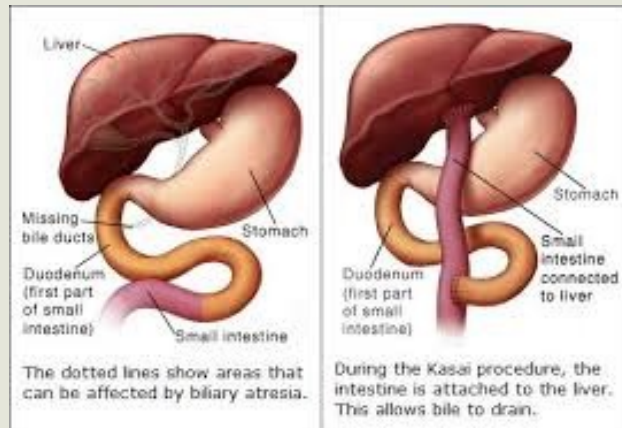
72

HIDA Scan



73

Kasai



74

Biliary Atresia-Kasai

- 1/3 fail-severe liver disease
- 1/3 indeterminate-moderate liver disease
- 1/3 "cured"-minimal liver disease
- Cholangitis
- Portal hypertension-esophageal varices
- Hypersplenism
- Fat-Soluble vitamin deficiency
- Zinc deficiency

75

Case 15

A 2 month old presents with jaundice. On exam, patient has hepatomegaly and the stools are clay-colored.

Which of the following studies is diagnostic?

- a) No gallbladder seen on US
- b) Lack of excretion on radionuclide scan
- c) Elevated liver functions, especially the GGT
- d) Obstruction on cholangiogram

76

Case 16

A 12 yr old girl has recurrent bouts of scleral icterus, often after viral illnesses. She is otherwise well and is taking no meds. Labs reveal: Total Bili of 3.4 mg/dl with direct Bili of 0.3 mg/dl. ALT/PT/APPT are all normal.

The most likely cause of the hyperbilirubinemia is?

- a) Chronic active hepatitis
- b) Dubin-Johnson syndrome
- c) Gilbert syndrome
- d) Hepatitis A
- e) Infectious Mononucleosis

78

Gilbert

- Mutations in UDPGT enzyme
- Mild unconjugated bilirubinemia
- Never about 4, GGT is normal

80

Alpha-1-Antitrypsin Deficiency

- Glycoprotein produced by hepatocytes
- Inhibitor of: neutrophil elastase acid proteases of alveolar macrophages
- Over 75 different protease inhibitors
- Co-dominant inheritance
- Z allele is associated with liver/lung disease: test for level and phenotype
- Most common genetic cause of liver disease in children
- Nonspecific clinical features: splenomegaly, frequent pneumonias/bronchitis, hepatomegaly

81

Case 17

A 15 yr old female is being evaluated for symptoms of depression associated with frequent mood swings. She is described as “an emotional rollercoaster” by her parents. On exam, concentric circular densities are noted in the cornea, as is hepatomegaly.

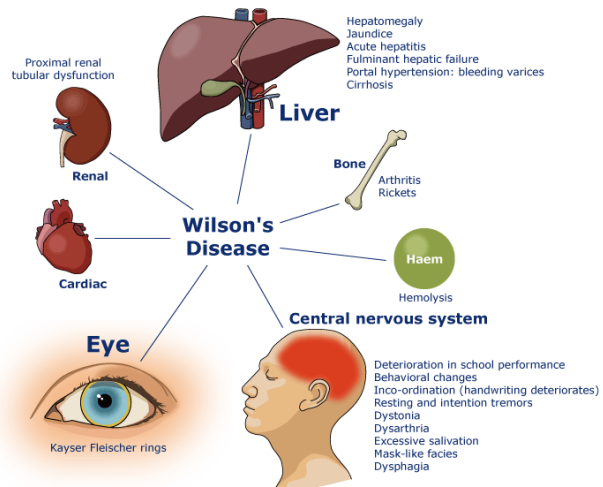
Which of the following tests will confirm the diagnosis?

- a) Alpha-fetoprotein level
- b) Serum haptoglobin level
- c) Total iron binding capacity
- d) Ceruloplasmin levels
- e) Free erythrocyte protoporphyrin

82

Wilson's Disease

- Children and Adolescents
- Disorder of copper metabolism
- Labs: coagulopathy, elevated liver enzymes, low platelets, low albumin
- Low ceruloplasmin
- 24 hour urine copper elevated
- Kayser fleischer rings
- Chelation is treatment- penicillamine



84

Case 18

A previously well 10 yr old has fever and persistent vomiting. Initially the emesis was clear, then bile-stained and now it contains bright red blood. Brother has AGE 1 wk ago. PE and CBC/BMP are normal.

The most likely cause of the hematemesis is:

- a) Esophageal varices
- b) Esophagitis
- c) Gastric duplication
- d) Mallory-Weiss tear
- e) Peptic ulcer disease

85

Upper GI Bleeding

- Hematemesis-Rapid bleeding lesion
- Coffee ground emesis-Slower bleed
- Hematochezia
- Melena

87

Upper GI Bleeding

- Esophagitis
- Gastritis
- Ulcer disease
- H. pylori
- Mallory-Weiss Tear
- Caustic Ingestion/Foreign Body
- Esophageal varices
- Esophageal and gastric tumors
- Vascular anomalies
- Coagulopathy
- Varices
- Duplication of gut
- IBD
- HSP
- Munchausen's syndrome by proxy

88

Lower GI Bleed – 0 to 30 days

- Anorectal lesions
- Swallowed maternal blood (APT test)
- Milk allergy
- NEC
- Midgut volvulus
- Hirschsprung's disease

89

Lower GI bleed – 30 days to 1 yr

- Anorectal lesions
- Milk Allergy
- Intussusception
- Meckel's diverticulum
- Infectious diarrhea
- Hirschsprung's disease

90

Case 19

For the past 6 wks, a 4 yr old has had painless, bright red rectal bleeding assoc with bowel movements. PE of abdomen and anus are normal. The rectal vault is empty and no blood is noted on gross inspection.

The most likely cause of the hematochezia is:

- a) Hemolytic-Uremic syndrome
- b) Henoch-Schonlein purpura
- c) Intussusception
- d) Juvenile Polyp(s)
- e) Meckel's diverticulum

91

Lower GI Bleed – 1-12 years

COMMON:

- Anal fissure
- Juvenile polyp
- Meckel's diverticulum
- Infectious diarrhea
- IBD

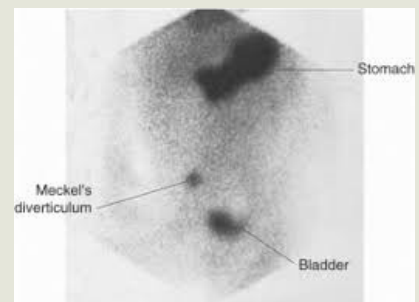
LESS COMMON:

- Henoch-Scholein purpura
- Hemolytic uremic syndrome
- Intestinal duplication
- Hemorrhoids

93

Meckel Diverticulum

- Painless rectal bleeding
- < 4 years of age
- Failure of omphalomesenteric duct to obliterate
- 2% of population
- Within 2 feet of ileocecal valve
- Meckel scan-technetium 99m pertechnetate scan
- Surgical removal



94

Ulcers-Risk factors

- NSAIDS
- H.pylori
- Crohn's
- Physical stress
- Celiac disease

95

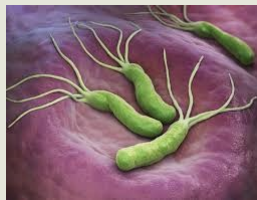Ulcer Disease Treatment

- H2 blockers-block the action of histamine and histamine H2 receptors of parietal cells in the stomach; this decreases acid production.
- PPI- inhibit the K^+/H^+ pump (potassium pump) located on the apical membrane of the gastric parietal cell, inhibiting secretion of H^+ into the stomach.
-longer duration of action than H2 blockers
- Sucralfate: aluminum hydroxide. DO NOT USE in renal failure

96

Helicobacter Pylori

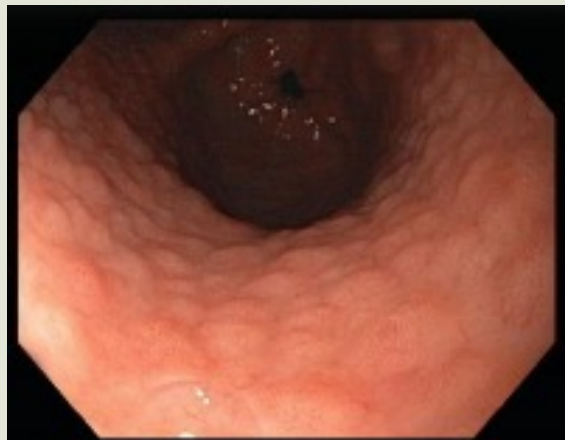- Associated with peptic ulcer disease
- Fecal-oral route or oral-oral route
- Chronic infection causes atrophic and even metaplastic changes in the stomach
- Symptoms:
 - Nausea
 - Vomiting
 - abdominal pain
 - heartburn



97

H.Pylori diagnosis

- Breath Test
- Endoscopy-nodularity
- Stool antigen-after treatment, not for initial diagnosis
- 2 antibiotics for 2 weeks, PPI x 2 months



98

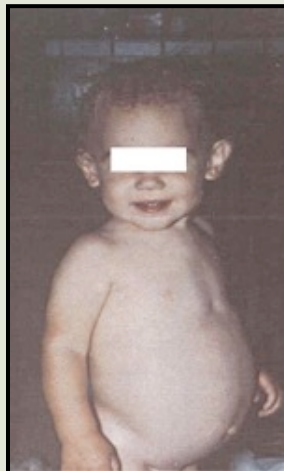Celiac Disease

- Autoimmune
- Triggered by gluten ingestion
- Associated with high risk populations
 - Type 1 DM
 - Down syndrome
 - Chronic lymphocytic thyroiditis (Hashimoto)
 - Williams
 - Turner
 - Family history

99

Celiac Disease-Classic

- Abdominal pain
- Abdominal distention
- Anorexia
- Failure to thrive/weight loss
- Diarrhea
- Irritability



100

Celiac Disease-non GI manifestations

- Dermatitis herpetiformis
- Dental enamel hypoplasia
- Osteopenia/osteoporosis
- Short stature
- Hepatitis
- Mouth sores
- Arthritis
- Neuropathy
- Iron deficiency anemia
- Seizure disorders
- Depression/anxiety
- Fertility disorders

101

Testing for Celiac

	Sensitivity %	Specificity %
AGA-IgG	69 – 85	73 – 90
AGA-IgA	75 – 90	82 – 95
EMA (IgA)	85 – 98	97 – 100
TTG (IgA)	90 – 98	94 – 97

- Need total IgA measurements
- HLA tests: DQ2/DQ8; asymptomatic relatives, diagnostic dilemmas

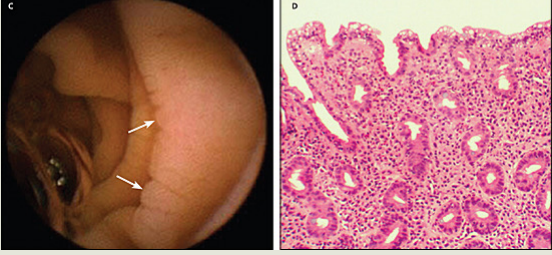
102

Endoscopy for Celiac



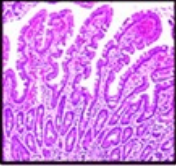
A

B

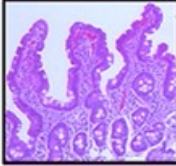


C

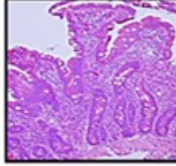
D



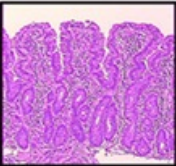
Normal
Marsh 0



Marsh 1



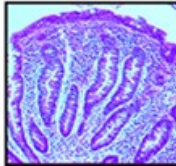
Marsh 2



Marsh 3a
Partial atrophy



Marsh 3b



Marsh 3c
total atrophy

103

Case 20

A 3 yr old boy with trisomy 21 presents with weight loss, frequent diarrhea and irritability. The growth curve indicates that his weight is below the 3rd percentile. Abdominal distention and decreased subcutaneous fat are noted on physical exam.

Which of the following laboratory studies are essential in order to provide an accurate diagnosis?

- a) Total protein and pre-albumin
- b) Serum IgA antibody levels
- c) Liver function tests
- d) Complete blood count
- e) Thyroid function tests

104

Case 21

A 6 yr old white female presents with long standing history of poor weight gain, frequent episodes of diarrhea and anorexia. Symptoms do not worsen or improve when she alters her dietary intake of dairy products. On laboratory screening she is mildly anemic. Sweat chloride results are normal. Due to concerns for celiac disease, TTG antibodies are sent. Results are normal.

Which of the following may lead to false negative result of TTG in patients with clinical features that are suggestive of celiac disease?

- a) Selective IgA deficiency
- b) Chronic persistent hepatitis
- c) Chronic granulomatous disease
- d) Treatment with immunoglobulin within the previous 6 months
- e) Hyper-IgE syndrome

106

Treatment of Celiac Disease

- Strict, lifelong avoidance of gluten
- Wheat, barley, rye
- Malt (barley extract)
- Hidden sources: medications, toothpaste, play do, paper straws, envelopes, stamps

108

Refeeding Syndrome

- Malnourished patients
- Electrolyte abnormalities
- Hypophosphatemia presents after first 48-72 hours
- Fluid retention
- Careful monitoring and slow refeeding; start with less than 50% of caloric goal, watch electrolytes every 6-8 hours and correct derangements
- Edema, muscle weakness, arrhythmias

109

Case 22

Compared to human milk, cow milk formula is more likely to contain which one of the following?

- a) More essential fatty acids
- b) Higher protein concentration
- c) Increased lactose content
- d) Lower Calcium-phosphate ratio
- e) Lower iron concentration

110

Human Milk

- Low protein (very bio-available)
- High lactose Low iron (very bio-available if taken alone)
- Low Calcium-Phosphate ratio
- Inadequate Vitamin K-can predispose to hemorrhagic disease of the newborn
- inadequate Vitamin D-need supplementation
- Immunoglobulins (including SIgA)

112

Formula Feeding

- Goat's milk leads to megaloblastic anemia due to folate deficiency
- Soy 50% cross reactivity for babies with milk protein intolerance
- Lactose intolerance is very rare in infants; primary carbohydrate source in breast milk; versus milk protein intolerance which causes proctocolitis

113

Case 23

A previously healthy 15 month appears pale. He has been fed goat milk exclusively since birth. Labs reveal: Hb=6.1, WBC=4800, plt=144K, MCV=109. Diff is 29% polys, 68% lymphs, 3% monos. Polys are hypersegmented.

What is the most likely cause of lab findings?

- a) ALL
- b) Fanconi anemia
- c) Folate deficiency
- d) Iron deficiency
- e) Vitamin B12 deficiency

114

Iron deficiency anemia

- Infants lose iron stores by 6 months
- Major nutritional deficiency in the USA
- Symptoms:
 - Brittle nails
 - Cracks on sides of mouth
 - Enlarged spleen
 - PICA
 - fatigue

116

Caloric requirements by age

- Infants require 80-120 cal/kg/day depending on gestational age
- Adolescent girls require 2500 cal. Boys 2500-3000.
- Only a starting point, needs vary by medical conditions etc.

117

Case 24

An adolescent girl on a strict vegan diet is most likely to develop deficiency of which of the following water-soluble vitamins?

- A) Folic acid
- B) Niacin
- C) Riboflavin
- D) Cobalamin
- E) Thiamine

118

Vitamin Sources and deficiencies

- Thiamine (B1)-grains, cereals, legumes
-beriberi, cardiac failure



- Pyridoxine (B6) – all foods
-dermatitis, cheilosis, glossitis, peripheral neuritis, irritability


- Riboflavin (B2) – dairy, meat, poultry, leafy vegetables
- seborrheic dermatitis, cheilosis, glossitis



120

Vitamin sources and deficiencies

- Niacin (B3) – meats, poultry, fish, wheat
- pellagra (diarrhea, dermatitis, dementia), glossitis, stomatitis



- Biotin (B7) – yeast, liver, kidney, legumes, nuts
- organic acidemia, alopecia, seizures



121

Vitamin Sources and deficiencies

- Folic acid (B9) – leafy vegetables, fruits, grains

-megaloblastic anemia, FTT



- Vitamin C – fresh fruits and vegetables

-scurvy, poor wound healing, bleeds

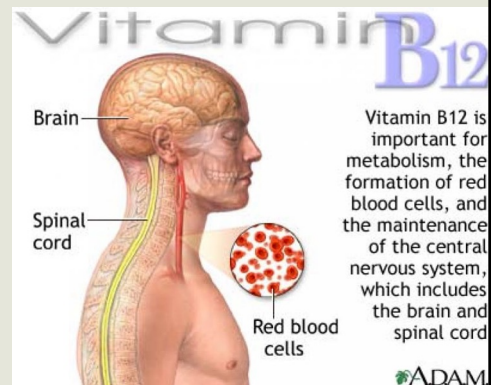
122

Vitamin sources and deficiencies

- B12 (Cobalamin) – eggs, dairy, meats (not in plants)

- Macrocytic anemia


- Bowel resection is a risk and may require supplementation, particularly terminal ileal resection



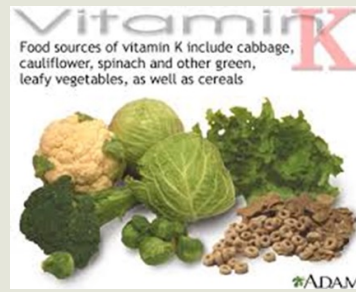123

Fat Soluble Vitamin Deficiencies

- A – night blindness, xerophthalmia, Bitot spots, keratomalacia



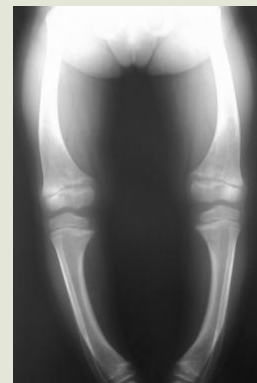- K - coagulopathy



124

Vitamin D deficiency

- Rickets-softening of bones before closing of epiphysis
 - May occur with chronic liver disease, due to decreased bile salts in the gut and decreased absorption of Vitamin D
 - Breast fed babies are more susceptible
- Generalized hypotonia
- frontal bossing
- craniotabes



125

Fat soluble vitamin deficiencies

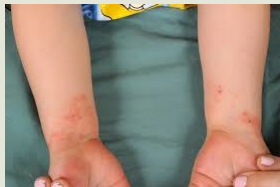- E –Anti-oxidant, maintains cell membrane integrity
- Part of immune system; protects scar tissue and inflammation
- Neurologic consequences, ataxia, ocular palsy, decreased DTRs



126

Mineral deficiencies

- Zinc: acrodermatitis enteropathica-dry skin, poor wound healing, perioral rash



- Cooper: menke's kinky hair syndrome

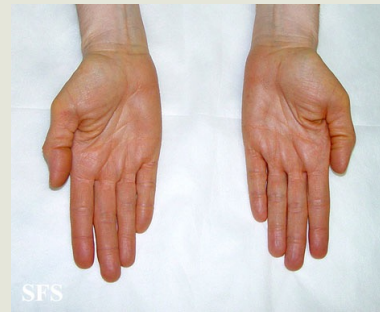
127

Case 25

An 8 month old white infant is noted to have yellow skin. The sclera are normal in color and the remainder of the physical exam is normal including neurologic assessment.

Of the following, which is the most useful diagnostic test:

- A) Measure serum bilirubin level
- B) Measure urine urobilinogen concentration
- C) Measure serum Vitamin A level
- D) Evaluate dietary history
- E) Measure serum T4 level



128

Tube Feeding

- Complications:
 - NG tube feeds: aspiration
 - ostomy feeds: wound infections, reflux, diarrhea
- Advantages:
 - enteral feeds maintain integrity of gastric mucosa
 - stimulate recovery of digestive enzymes
 - jejunal tubes: decrease risk of aspiration/reflux but have risks of obstruction

130

Indications for tube feeds

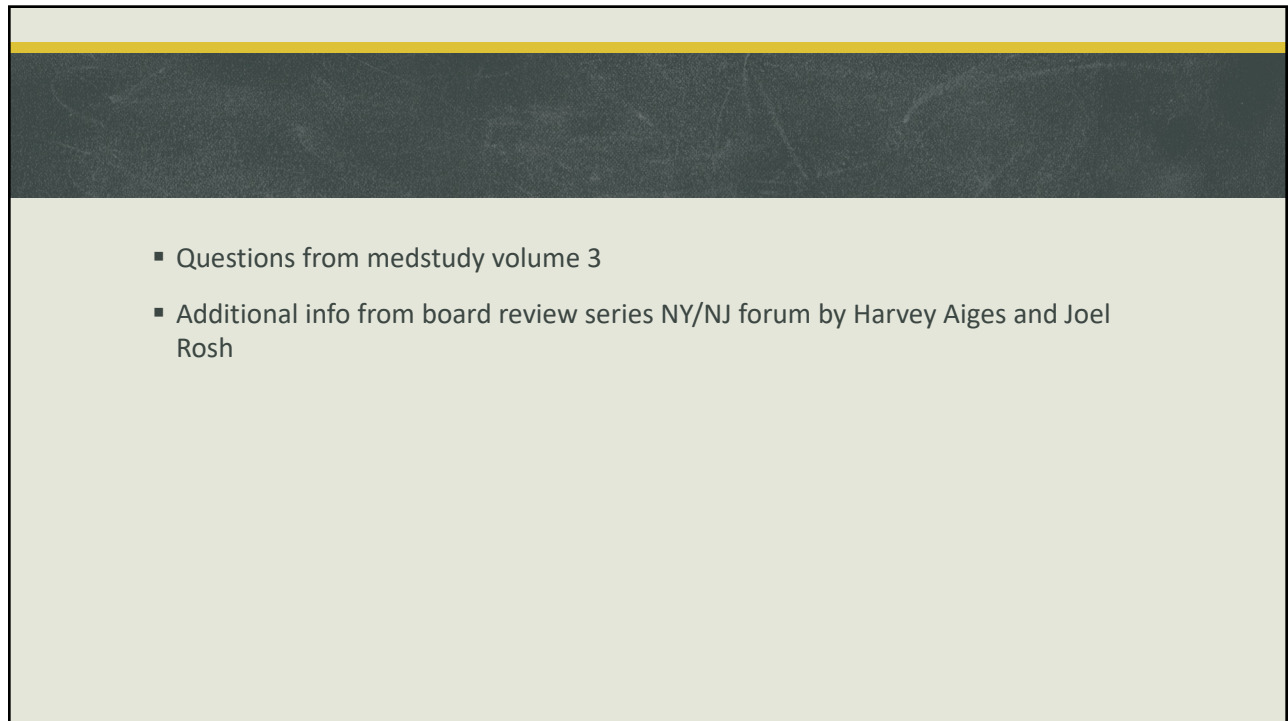
- Eating/swallowing disorders and/or inability to maintain proper nutrition: prematurity, short bowel syndrome, neurologic conditions, CF, short bowel syndrome
- Unconscious patients
- Continuous feeds:
 - congenital heart disease kids: have increased metabolic demand
 - IBD kids: malabsorption states

131

Parenteral nutrition

- Indicated in short bowel, poor peristalsis, intestinal obstruction, trauma/burns
- PN solution: 60-70% calories from glucose, 30% from lipids, remainder are amino acids.
 - add multivitamins and trace elements
- Monitor electrolytes weekly and trace elements monthly

132



- Questions from medstudy volume 3
- Additional info from board review series NY/NJ forum by Harvey Aiges and Joel Rosh

133