SCIENTIFIC ARTICLE

Remodeling Potential of Phalangeal Distal Condylar Malunions in Children

Benjamin N. Puckett, MD, R. Glenn Gaston, MD, Allan E. Peljovich, MD, Gary M. Lourie, MD, Waldo E. Floyd III, MD

Purpose Distal condylar phalangeal (DCP) fractures in children are uncommon, but their periarticular location makes them problematic. Malunions are particularly difficult to treat. These fractures are generally thought to have a poor remodeling potential because their location is far from the phalangeal physis. We present 8 cases of DCP malunion in children with a mean 5-year follow-up demonstrating consistent remodeling.

Methods In this study, DCP fractures were defined as those occurring at or distal to the collateral ligament recess of the proximal or middle phalanx in skeletally immature patients. Radiographic parameters examined at the time of established malunion and at final follow-up included coronal and sagittal plane deformity and translational malalignment of the distal fragment in relation to the proximal shaft. Range of motion was measured, and a brief questionnaire was implemented to establish patient satisfaction.

Results We examined 8 patients with a minimum 1-year follow-up (mean, 5.3 y). Average age at injury was 8.8 years (range, 2–14 y). In the sagittal plane, fractures remodeled from an initial mean deformity of 30.9° to 0.0°; in the coronal plane, from 10.5° to 3.9°. Fracture translation in the sagittal plane corrected, as well, from a mean 57.5% at injury to 0.0% at final follow-up. There was no functionally limiting loss of motion of the digit in any patient. Subjectively, only 2 patients complained of cosmetic deformity, both of which were coronal plane deformities of the small finger.

Conclusions In this case series, DCP malunions in children remodeled significantly and completely in the sagittal plane, and all patients had good final range of motion. Furthermore, patients were satisfied with nonsurgical treatment at long-term follow-up. This series describes the remodeling potential of DCP fractures in children, lending support to the previously reported cases. These findings support treating late-presenting pediatric DCP malunions nonsurgically. *(J Hand Surg 2012;37A:34–41. Copyright © 2012 by the American Society for Surgery of the Hand. All rights reserved.)*

Type of study/level of evidence Therapeutic IV.

Key words DCP, finger, phalangeal neck fracture.

Most phalangeal fractures in children are periphyseal.[1,2] Minimally displaced fractures are managed with protected immobilization, and in the case of displacement, most can be managed by simple reduction and immobilization, with surgery infrequently required.[3,4] It is a basic premise in pediatric orthopedics that periphyseal fractures in children have excellent remodeling capability and that remodel-

From the Pediatric Hand and Upper Extremity Program, Childrens Healthcare of Atlanta, Atlanta, GA; Atlanta Medical Center Orthopaedic Residency Program, Atlanta, GA; Hand and Upper Extremity Center of Georgia, Atlanta, GA; Macon Orthopaedic and Hand Center, Macon, GA.

Received for publication June 24, 2010; accepted in revised form September 16, 2011.

No benefits in any form have been received or will be received related directly or indirectly to the subject of this article.

Corresponding author: Allan E. Peljovich, MD, The Hand & Upper Extremity Center of Georgia, 980 Johnson Ferry Rd., NE #1020, Atlanta, GA 30342; e-mail: DrP@HandCenterGA.com.

0363-5023/12/37A01-0007$36.00/0
doi:10.1016/j.jhsa.2011.09.017

ing potential lessens with increasing distance from the growth plate. In addition to the presumed poor remodeling capacity, fractures of the distal aspect of the proximal and middle phalanx are inherently unstable and problematic fractures.[5,6] We refer to these fractures that occur distal to the collateral ligament recess as *distal condylar phalangeal (DCP) fractures*, but other nomenclature in the literature includes subcondylar, subcapital, cartilage cap, supracondylar, unicondylar, bicondylar, avulsion, transcondylar, and phalangeal neck fractures.[7–10]

Most authors recommend closed reduction and percutaneous pinning of displaced DCP fractures acutely, based on the need to maintain articular alignment, their inherent instability, and poor remodeling potential.[11,12] Unfortunately, many of these injuries present in a delayed manner due to factors such as inadequate injury radiographs or that the family or treating physician feels that the injury is minor. Subacute or delayed presentations of displaced DCP fractures present an even greater challenge to the treating physician. Techniques such as percutaneous osteoclasis or open osteotomy have been described to address this problem early, and subcondylar fossa recession has been recommended to treat late malunions, with their expected loss of flexion.[13,14]

A small number of case reports have shown remodeling of these injuries to occur in young children.[15–18] We present a series of 8 DCP malunions with a 5.3-year mean follow-up, demonstrating the impressive remodeling capability of these fractures.

MATERIALS AND METHODS

We defined a DCP fracture as one occurring at or distal to the collateral ligament recess of the proximal or middle phalanx. A DCP malunion is further defined as a healed or healing (callus present but less than 3 weeks from injury) fracture with any degree of malalignment in the sagittal or coronal plane. In this series, 7 patients presented to our institution in a delayed fashion with a DCP malunion as defined earlier. One child (patient 8) was treated with immobilization for a displaced DCP fracture and allowed to heal with a malunion as outlined later.

Following institutional review board approval, we identified by chart review 17 patients who had presented with a healed or healing malunion between 1997 and 2007. Eight of these 17 patients had surgery to correct the malunion and were, therefore, unable to be assessed for subsequent remodeling. Nine were treated nonsurgically, with the option of a late subcondylar fossa reconstruction if needed. None of the 9 patients who were observed required a late surgical procedure.

TABLE 1. Demographic Data

Patient No.	Injured Digit	Age at Injury	Follow-Up (mo)
1	L index P2	2 y	19
2	R index P2	10 y	21
3	R small P1	14 y	82
4	R small P1	12 y	78
5	R small P1	12 y	108
6	L small P1	6 y	111
7	R index P2	14 y	84
8	L small P1	6 mo	12

P1, proximal phalanx, P2, middle phalanx.

Of the 9 patients, 7 were able to be contacted and returned for a long-term follow-up (patients 1–7). One patient was lost to follow-up and could not be found, and the other patient was contacted by phone. This patient was now in college, too far away to return for follow-up, but he did note over the phone that he had no problems with the finger and felt that he had full range of motion and function of the injured finger.

Patient 8 was treated nonsurgically for a late presenting malunion by a hand surgeon at a second institution and added to the study. This was a 6-month-old patient who had a closed reduction and casting acutely, then at 3 weeks the reduction was lost and the patient was observed. This particular case is more appropriately termed a displaced DCP fracture allowed to heal and remodel rather than a DCP malunion at the time of presentation, but the patient has been included in the study because the natural history parallels the other study patients. Including patient 8, we were able to follow up with 8 of 10 patients in the office, and 1 patient by phone.

Average age at injury was 8.8 years (range, 2–14 y), and average time to final follow-up was 5.3 years (range, 1—9.25 y). Demographic data included patient age at injury, the involved finger, and the involved phalanx (Table 1).

Radiographic parameters examined at the time of established malunion and at final follow-up included coronal and sagittal plane angular malalignment, as well as the percentage of translation of the distal fragment relative to the shaft. Coronal and sagittal plane alignment was measured with one line drawn down the longitudinal axis of the phalanx and one line perpendicular to the articular surface. The angle of these intersected lines was recorded to the nearest degree with a goniometer. Translation was reported as the percent-

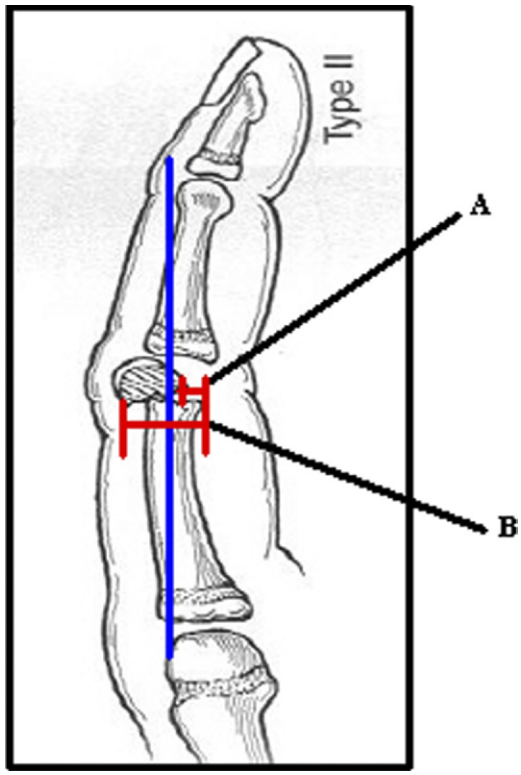

FIGURE 1: Measurement of translational deformity or 'volar spike' component. Percent fracture translation = A/B × 100.

age of translation of the distal fragment relative to the mid-axial point of the shaft on the lateral image (Fig. 1). The percentage of translational displacement was quantified in an effort to describe the volar spike component that presumably blocks flexion of the affected joint. Range of motion was determined at the final follow-up visit, using a goniometer placed along the dorsum of the digit centered over the involved joint. Each patient was asked to grip a pencil in each hand to determine whether there was any rotational deformity. Subjective patient satisfaction was determined with a brief, 6-question survey (Table 2).

Statistical methods

Statistical analysis was performed using 2-tailed *t*-tests with SAS software (Statistical Analysis System, Cary, NC), with significance set at ≤ 0.05 in all cases.

RESULTS

The results are summarized in Table 3. In the sagittal plane, fractures remodeled from an initial deformity mean of 30.9° (range, 8° to 90°) to 0.0° (range, 0.0° to 0.0°) ($P = .016$) (Fig. 2).

Fracture translation in the sagittal plane corrected from a mean 57.5% (range, 10% to 100%) to 0.0% (range, 0.0% to 0.0%) ($P < .01$) (Fig. 3). In the coronal plane fractures, 4 patients remodeled to varying degrees, but this remodeling did not reach statistical significance ($P = .15$). The average initial coronal plane deformity was 10.5° (range, 4° to 34°), and the final average coronal deformity was 3.9° (range, 0° to 8°).

Final joint range of motion was compared to the opposite hand and found to be minimally different clinically, but statistically significant ($P = .04$). On average, patients regained 97.5% (range, 94% to 100%) flexion, with only 2.4° loss of motion compared to the contralateral hand. None of the patients noted a loss of motion clinically. Change in extension was increased 0.3° in the injured finger compared to the contralateral hand, which was clinically and statistically insignificant ($P = .35$). We noted no clinical rotational deformities at final follow-up. Subjectively, only 2 patients complained of cosmetic deformity (patients 3 and 4), both of which were ulnar coronal deviation deformities of the small finger. Otherwise, there were no subjective complaints.

TABLE 2. Brief Subjective Questionnaire

Do you have any complaints or are you unhappy in any way with your treatment?
Do you have difficulty writing or drawing?
Do you have trouble grasping objects?
Do you have trouble putting your hands in and out of your pockets, or with taking objects in or out of your pockets?
Do you have any pain?
Do you have a cosmetic deformity that concerns you?
If anything could be done surgically to change your outcome, would you change it?

DISCUSSION

Fractures that involve the distal condylar area in children require careful attention. Unlike periphyseal fractures, periarticular DCP fractures can be associated with a loss of motion. Treatment requires monitoring of alignment because maintaining alignment of the joint tends to confer better motion. When displaced, these fractures are treated with surgery, most commonly reduction and percutaneous pinning, to restore alignment.[12]

All DCP fractures tend to be unstable and displace into a volar apex, dorsally angulated pattern.[5] This deformity can cause considerable morbidity due to loss of the subcondylar fossa, which creates a mechanical block to full digital flexion. The unstable nature of these injuries and the problems associated with malalignment

TABLE 3. Patient Data

Patient No./ Age at Injury	Initial Sagittal Plane Deformity (° Dorsal Angulation)	Final Sagittal Plane Deformity (° Dorsal Angulation)	Initial Coronal Plane Deformity (° Ulnar Deviation)	Final Coronal Plane Deformity (° Ulnar Deviation)	Percent Initial Translational Deformity	Percent Final Translational Deformity	Clinical Rotational Deformity at Final Follow-Up	Final Range of Motion (° Extension and Flexion)*	Complaint at Final Follow-Up
1/2 y	52	0	4	4	75%	0%	None	L index DIP 0–66 (0–68), 97%	None
2/10 y	8	0	4	1	10%	0%	None	R index DIP 0–75 (0–75), 100%	None
3/14 y	30	0	4	4	100%	0%	None	R small PIP 0–98 (0–98), 100%	Cosmetic
4/12 y	16	0	8	8	25%	0%	None	R small PIP 8–118 (6–12), 94%	Cosmetic
5/12 y	12	0	8	8	50%	0%	None	R small PIP 0–102 (2–104), 98%	None
6/6 y	15	0	10	3	60%	0%	None	L small PIP 0–77 (0–80), 96%	None
7/14 y	24	0	12	3	40%	0%	None	R index DIP 0–70 (0–74), 95%	None
8/6 mo	90	0	34	0	100%	0%	None	L small PIP 0–90 (0–90), 100%	None

DIP, distal interphalangeal joint; PIP, proximal interphalangeal joint.
*Final range of motion (contralateral side in parentheses), percent of flexion regained compared to contralateral hand.

FIGURE 2: Lateral radiographs. **A** Patient 8 at injury (6 months of age). **B** Patient 8 at 2 months after injury. **C** Patient 8 at 11 months after injury, demonstrating full remodeling. **D** Patient 3 at 14 years of age. **E** Patient 3 at 2 months after injury. **F** Patient 3 at 82 months after injury, demonstrating full remodeling.

have led previous authors to recommend that displaced distal condylar fractures be treated with closed or open reduction followed by percutaneous pinning.[5,12] These recommendations hold, especially in light of their presumed poor remodeling potential.

A number of patients who sustain DCP fractures will present in a delayed manner. It is not uncommon that the injury is felt to be innocuous by the family or the initial treating physician or that adequate radiographs are not initially obtained. We have also observed that referring physicians might treat these injuries like their periphyseal cousins, with buddy-straps or flexible aluminum splints, unaware of their unstable nature. Late-presenting malunions with advanced healing pose a challenge. To re-establish a subcondylar fossa and improve range of motion, authors have recommended open osteotomy up to 3, 4, and even 6 weeks after the initial injury.[12,19] The problem is that, although open osteotomy can restore radiographic alignment, the expected increase and restoration of motion is rarely seen due to the extensive soft tissue stripping and scarring that these open procedures create.[13] Open osteotomy also carries the risk of avascular necrosis due to the tenuous collateral blood supply of the distal phalanx.[20]

FIGURE 3: Lateral radiographs. **A** Patient 5 at injury (12 years of age), with considerable volar spike or translational component. **B** Patient 5 at 108 months after injury, showing complete remodeling of the translational deformity.

Beyond 6 weeks, the fracture has likely healed, and Simmons and Peters advocated a late subcondylar fossa reconstruction to restore the flexion–extension arc.[14] More recently, and for fractures presenting with malunion within a few weeks of injury, Waters has demonstrated that a closed, percutaneous osteoclasis can effectively restore radiographic alignment without the soft tissue problems faced with a more traditional osteotomy and can reliably restore mobility.[13] The problem remains, however, that some children present too late for a percutaneous osteoclasis or the family does not desire surgery right away, preferring to wait.

All surgical techniques for this difficult to treat problem are based on the premise that, because phalanges have growth plates at their proximal end, there is minimal remodeling potential at the distal aspect of the phalanx. Several authors have reinforced this thought process and, thus, recommended surgical treatment of late-presenting distal condylar fractures.[4,11,21] In contrast, Ogden et al offered 2 mechanisms whereby remodeling distal from the growth plate might indeed occur.[22,23] Bone formation under an elevated periosteum might contribute to correcting an angular deformity, and forces consistent with Wolff's law in the flexion–extension plane might promote remodeling, such as in the subcondylar fossa. In fact, over the last several years, surgeons have recognized this remodeling potential at the distal phalanx, and 5 cases have been reported in the literature.[15–18] Although all of these 5 children were young (the oldest being 7 y old), all patients regained good range of motion, with 4 of 5 reportedly regaining full range of motion.

These case reports have shed new light on the natural history of distal condylar fractures in demonstrating that remodeling can occur at the distal aspect of the phalanx, contrary to previous thinking. Cornwall and Waters stated that although previous case reports "add support to the conclusion that such remodeling *can* occur, we cannot conclude from these single cases, however, how often or under what circumstances (like fracture type, degree of angulation, or patient age) such remodeling is *likely* to occur." [18] In the 2 senior authors' practices over a 10-year period, 9 late-presenting malunions of 101 DCP fractures were treated nonsurgically, and we were able to follow up with 88 total patients, including 1 patient contributed by a third surgeon. All of these injuries were extension-type fractures, and all remodeled, regardless of age or degree of angulation. Previously, there have been no reports of remodeling in a child over the age of 7 years for this fracture type.[15] Based on the ages of the case reports, Waters stated that only young children have the potential to remodel.[24] In our series, 2 patients were 14 years old at initial injury, and 2 patients were 12 years old; all 4 of these patients

completely remodeled in the sagittal plane. All patients had open growth plates at the time of injury. It appears that the presence of an open growth plate, rather than the chronological age, is more predictive of remodeling potential in the distal aspect of the phalanx. Not addressed in this series is larger coronal plane or rotational malunions. Based on the increased predilection for functional impairment, these types of malunions might require surgery more frequently, and they likely have lower capacity to remodel.

Our average follow-up was 5.3 years, and we found no complications resulting from nonsurgical treatment, which is consistent with previous case reports. In fact, all patients were happy with nonsurgical treatment and said that they would choose the same treatment again. All patients clinically regained full range of motion in the flexion–extension arc. We did, however, find that significant remodeling did not occur in the coronal plane ($P = .15$), and 2 of the patients complained of a cosmetic deformity. Both of these patients had an ulnar deviation deformity of the small finger, which they both felt was an acceptable malalignment. In their original criteria for nonsurgical treatment, Cornwall and Waters predicted that coronal and rotational malalignment would not remodel and were, therefore, indications for surgery.[18] We have found this prediction to be true, in that our patients did not have significant remodeling in the coronal plane ($P = .15$). No rotational deformities were known to be present at the time of initial presentation or at final follow-up.

Due to their inherent instability, when distal condylar fractures are diagnosed acutely and displaced, they should be treated with surgical reduction and fixation, which can usually be accomplished with closed manipulation and percutaneous pinning. For incipient malunions presenting between 2 and 5 weeks of injury, the patient and parents can be offered the options, such as of percutaneous osteoclasis described by Waters et al or nonsurgical treatment with periodic follow-up.[13] Waters specifically addressed this clinical scenario and similarly recommended that patients could be given an option but that surgically correcting these injuries would resolve the patient's problem more rapidly, thereby improving range of motion more quickly.[24] He also prefaced this recommendation by saying that nonsurgical treatment was only an option in, specifically, young patients. We agree with these assessments, but note that our study suggests that older children are also quite capable of remodeling.

Limitations of this study would be lack of a randomized, prospective nature and a lack of interobserver reliability analysis. Despite the lack of randomization, we had minimal selection bias, in that all patients were treated within our original algorithm: all patients presenting between 2 and 4 weeks were treated surgically, and all those presenting after 4 weeks were treated with observation. This does raise the question of whether patients presenting between 2 and 4 weeks will obtain an advantage with surgical intervention compared to observation. Still, with the outstanding long-term clinical outcomes we have found in our patients treated nonsurgically, our current approach to treating these injuries is indeed altered by our study results. We continue to treat nondisplaced DCP fractures with casting and weekly re-evaluation to ensure that these fractures remain well aligned. For those children who present acutely and with displacement, we continue to recommend surgery to realign the fracture. For those children who present with a healing, incipient malunion, we have changed our treatment algorithm and now offer the parents either percutaneous osteoclasis or observation. Just as Waters described previously, we believe that the advantage of percutaneous osteoclasis might lie in the earlier return of mobility, but we recognize a greater remodeling potential than previously thought.[24] For those children who present late with a healed malunion, we recommend observation. If the fracture fails to remodel over time, we would offer a subcondylar fossa reconstruction. And finally, due to the excellent clinical outcome in patient 8, for young infants with short, adipose-laden fingers who portray the greatest remodeling potential and present with displaced fractures, we reserve the consideration for observation, even in the acute setting, when reduction and fixation can be challenging in the face of increased anesthetic risks.

For patients with established DCP malunions and open physes, we have found a consistent and effective remodeling capacity as previously reported. These fractures tend to remodel in the plane of motion, but they remodel to a lesser degree out of the plane of motion (coronal plane). Based on our results, the option of nonsurgical observation should be given to children, regardless of the degree of sagittal plane deformity, provided that they have open growth plates radiographically and acceptable coronal and rotational deformities. To date, nonsurgical recommendations for treating malunions of the distal aspect of the phalanx have been based on isolated case reports. With this long-term case series, we have found that complete remodeling in the sagittal plane occurred in all 8 of our patients when the growth plate was open. Further, when these injuries are treated nonsurgically, patients can regain excellent motion and realize good clinical outcomes.

REFERENCES

1. Graham T. Fractures and dislocations of the hand and carpus in children. In: Rockwood CA, Green DP (eds). Fractures in children, ed. 4, vol 3. Philadelphia: Lippincott, 1996:361–378.
2. Fischer MD, McElfresh EC. Physeal and periphyseal injuries of the hand. Hand Clin 1994;10:287–301.
3. Lindley SG, Rulewicz G. Hand fractures and dislocations in the developing skeleton. Hand Clin 2006;22:253–268.
4. Barton NJ. Fractures of the phalanges of the hand in children. Hand 1979;11:134–143.
5. Al-Qattan MM. Phalangeal neck fractures in children: classification and outcome in 66 cases. J Hand Surg 2001;26B:112–121.
6. Barton NJ. Fractures of the hand. J Bone Joint Surg 1984;66B:159–167.
7. Hastings H, Simmons BP. Hand fractures in children: a statistical analysis. Clin Orthop Relat Res 1984;188:120–130.
8. Al-Qattan MM, Cardoso E, Hassanain J, Hawary MB, Nandagopal N, Pitkanen J. Non-union following subcapital (neck) fractures of the proximal phalanx of the thumb in children. J Hand Surg 1999;24B: 693–698.
9. Dixon GL, Moon NF. Rotational supracondylar fractures of the proximal phalanx in children. Clin Orthop Relat Res 1972;83:151–156.
10. Wood VE. Fractures of the hand in children. Orthop Clin North Am 1976;7:527–542.
11. Green DP. Hand injuries in children. Pediatr Clin North Am 1977; 24:903–918.
12. Stern PJ. Fractures of the metacarpals and phalanges. In: Green DP, Hotchkiss RN, Pederson WC, eds. Green's operative hand surgery. 4th ed. New York: Churchill Livingstone. 1999:711–771.
13. Waters PM, Taylor BA, Kuo AY. Percutaneous reduction of incipient malunion of phalangeal neck fractures in children. J Hand Surg 2004;29A:707–711.
14. Simmons BP, Peters TT. Subcondylar fossa reconstruction for malunion of fractures of the proximal phalanx in children. J Hand Surg 1987;12:1079–1082.
15. Mintzer CM, Waters PM, Brown DJ. Remodeling of a displaced phalangeal neck fracture. J Hand Surg 1994;19B:594–596.
16. Hennrikus WL, Cohen MR. Complete remodeling of displaced fractures of the neck of the phalanx. J Bone Joint Surg 2003;85B:273–274.
17. Al-Qattan MM, Rasool MN, El Shayeb A. Remodeling in a malunited phalangeal neck fracture. Injury 2004;35:1207–1210.
18. Cornwall R, Waters P. Remodeling of phalangeal neck fracture malunions in children: case report. J Hand Surg 2004;29A:458–461.
19. Graham TJ, Waters PM. Fractures and dislocations of the hand and carpus in children. In: Beaty JH, Kasser JR, eds. Rockwood and Wilkins' fractures in children. 5th ed. Philadelphia: Lippincott Williams and Wilkins, 2001:269–379.
20. Yousif NJ, Cunningham MW, Sanger JR, Gingrass RP, Matloub HS. The vascular supply to the proximal interphalangeal joint. J Hand Surg 1985;10:852–61.
21. Barton NJ. Fractures of the shafts of the phalanges of the hand. Hand 1979;11:119–133.
22. Ogden JA. Skeletal Injury of the Child. 3rd ed. New York: Springer-Verlag, 2000:650–707.
23. Ogden JA, Ganey TM, Ogden DA. The biological aspects of children's fractures. In: Rockwood CA, Wilkins KE, Beaty JH, eds. Fractures in children. 4th ed. Philadelphia: Lippincott-Raven, 1996:19–52.
24. Waters PM, Tomaino MM. Letters to the editor: Percutaneous reduction of incipient malunion of phalangeal neck fractures. J Hand Surg 2005;30A:409–410.