Fractures of the Base of the Proximal Phalanx in Children

Remodeling of Malunion in the Radioulnar Plane With a Diaphyseal Axis–Metacarpal Head Angle of 156° to 163°

Mohammad M. Al-Qattan, MBBS

Background: The diaphyseal axis–metacarpal head angle (DHA) measures the angle between the axis of the proximal phalanx and the center of the metacarpal head. In unfractured fingers, the normal DHA ranges from 177.1° to 180.0°. The angle may be used to quantify the degree of lateral displacement of pediatric fractures of the base of the proximal phalanx. Previous authors have shown that if the postreduction x-rays show an angle greater than 169° remodeling with normalization of the DHA is expected to occur in children. The degree of remodeling of more severe angulations is unknown.

Patients and Methods: This is a retrospective study (over the last 5 years) that identified 8 late referrals (4–6 weeks after injury) of inadequately reduced pediatric fractures of the base of the proximal phalanx with a postreduction DHA of 156° to 163°. At the time of presentation to the author, there was lateral deviation of the finger, and the fracture site was not tender, indicating malunion. All patients were offered surgery, but this was refused by the parents. Follow-up appointments to the clinic were made, and the DHAs were serially measured to investigate the degree of remodeling.

Results: Seven patients had normalization of the DHA (ie, an angle >177°) between 9 and 18 months. In the remaining patient, the DHA was 175.7° at 2 years.

Conclusions: The current study shows adequate remodeling of severe residual angular deformities (DHA of 156°–163°). The clinical implication of this finding is regarding late referrals with no tenderness at the fracture site. In these cases, refracturing usually requires general anesthesia. Our study shows that patients may be given the option of conservative management awaiting remodeling.

Key Words: children, hand fractures, malunion, proximal phalanx, remodeling

(*Ann Plast Surg* 2019;82: 399–402)

The epidemiology of hand fractures in children is well studied in the literature.[1–3] The most commonly fractured bone in the pediatric hand is greatly influenced by the age group: the distal phalanx in young children, the proximal phalanx in the intermediate age group (9–12 years), and the metacarpal (including boxer's fractures) in children 13 to 18 years of age. The most common pediatric proximal phalangeal fracture is seen at the base of the phalanx, and almost 70% of these fractures are seen in the little finger.[3] The classic presentation is an ulnarly deviated little finger, and hence, the fracture is often referred to as the "extra-octave" fracture: The hand normally spans 8 piano keys, and this span increases with ulnar deviation of the little finger.[4,5]

In 2013, Al-Qattan et al[6] described the diaphyseal axis–metacarpal head angle (DHA) to quantify the degree of displacement of fractures of the base of the proximal phalanx in children. The line drawn through the center of the phalangeal head and the center of the metaphysis of the proximal phalanx normally passes through the center of the metacarpal head. The author showed that the normal DHA ranges from 177.1° to 180.0° with good interobserver and intraobserver reliability (Fig. 1). The authors also demonstrated that if the postreduction x-rays show an angle of greater than 169° remodeling with normalization of the DHA is expected to occur. Finally, the authors stated that remodeling of fractures with angles less than 169° is unknown and deserves further study. A postreduction DHA of less than 169° will be associated with an obvious lateral deviation of the finger. Hence, it will not be ethical to do such a study prospectively because fracture reduction will be considered inadequate and a second attempt at reduction will be done.

The author works at a tertiary care center and receives referrals with poorly managed fractures. Over the last 5 years, the author received 8 late referrals (4–6 weeks after injury) of inadequately reduced fractures of the base of the proximal phalanx in children with a postreduction DHA of 156° to 163°. All patients were offered surgery, but this was refused by the parents. This gave the author the opportunity to investigate remodeling of these fractures when the postreduction x-ray showed a DHA of less than 163°.

PATIENTS AND METHODS

The study was approved by the research committee of CARE Hospital. This is a retrospective study (over the last 5 years) that identified 8 late referrals (4–6 weeks after injury) of inadequately reduced pediatric fractures of the base of the proximal phalanx with a postreduction DHA of less than 163°. All fractures underwent a single attempt of reduction in the emergency room at a local hospital, and the hand was placed in a splint. At the time of presentation to the author (4–6 weeks later), there was lateral deviation of the finger, and the fracture site was not tender, indicating malunion. All patients were offered surgery, but this was refused by the parents. No splints or buddy tapes were used, and the children were allowed to use their hands freely. Follow-up appointments to the clinic were made, and the DHAs were serially measured to investigate the degree of remodeling.

The following data were collected: age, sex, fractured finger, fracture type, and the DHAs from the time of injury to final follow-up. The fracture type was classified as either a Salter-Harris or a juxtaepiphyseal (JE) fracture of the base of the proximal phalanx. The JE fracture is defined as a fracture located 1 to 2 mm distal to the growth plate of the proximal phalanx and is subclassified into 2 types.[7] In JE type I fractures, the fracture line is transverse along the metaphyseal subchondral bone. In JE type II fractures, the transverse fracture line involves a metaphyseal fragment at the ulnar or radial corner of the metaphysis. This fragment will mimic the Thurstan-Holland metaphyseal fragment of Salter-Harris II fractures (Fig. 2).

RESULTS

The results are summarized in Table 1. There were 5 boys and 3 girls, and the age range was 7 to 12 years. Seven patients had an

Received September 21, 2018, and accepted for publication, after revision November 26, 2018.
From the Division of Plastic Surgery, King Saud University; and the Division of Plastic Surgery, King Faisal Specialist Hospital and Research Center, Riyadh, Saudi Arabia.
The study was approved by the research committee of Riyadh National Hospital (CARE).
Conflicts of interest and sources of funding: The work was supported by the College of Medicine Research Center, Deanship of Scientific Research, King Saud University, Riyadh, Saudi Arabia. The author declares no conflict of interest.
Reprints: Mohammad M. Al-Qattan, MBBS, PO Box 18097, Riyadh 11415, Saudi Arabia. E-mail: moqattan@hotmail.com.

ISSN: 0148-7043/19/8204–0399
DOI: 10.1097/SAP.0000000000001816

FIGURE 1. The normal DHA (179.4°) in the unfractured finger and a 159.5° angle in the "extra-octave" fracture.

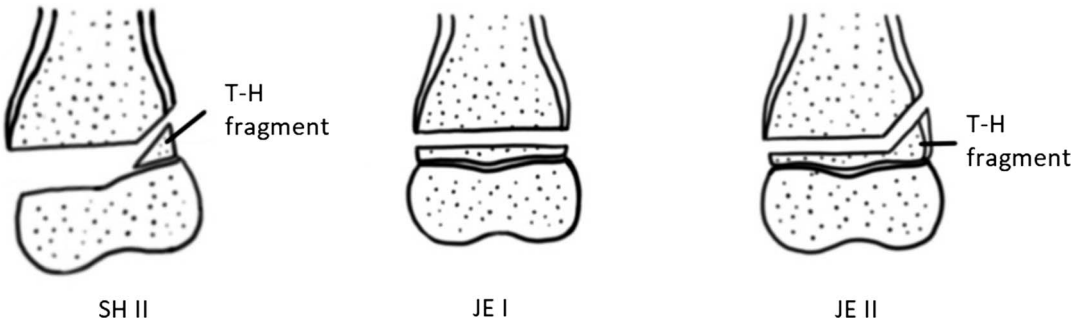

FIGURE 2. The most common fracture types at the base of the proximal phalanx in children: Salter-Harris type II fractures, which have a Thurstan-Holland (T-H) fragment and the 2 types of JE fractures. Note that JE II fractures also have a T-H fragment.

TABLE 1. Remodeling of Fractures of the Base of the Proximal Phalanx in Children Assessed by the DHA

				DHA			
Patient No.	Age, y/Sex	Fractured Finger	Fracture Type	At the Time of Injury	Immediately Post–Closed Reduction	At the Time of Presentation to Our Clinic (4–6 wk After Injury)	At Final Follow-up
1	10/M	LF	JE II	148.8°	157.3°	162.9°	175.7° at 2 y
2	8/M	LF	JE II	150.4°	156.2°	156.4°	177.9° at 1 y
3	9/M	LF	SH II	145.5°	X-ray not available	156.5°	178.7° at 1 y
4	10/F	LF	SH II	146.6°	155.9°	160.1°	177.9° at 14 mo
5	7/M	LF	JE I	158.4°	160.6°	161.9°	178.0° at 18 mo
6	8/M	LF	JE II	147.7°	157.8°	158.1°	179.0° at 16 mo
7	7/F	LF	JE II	149.8°	158.8°	158.8°	179.1° at 13 mo
8	12/F	RF	SH II	154.8°	X-ray not available	160.4°	178.9° at 9 mo

JE I, JE type I; JE II, JE type II; LF, little finger; RF, ring finger; SH II, Salter-Harris type II.

FIGURE 3. Case 1 (Table 1). A case of JE fracture type II. X-ray at the time of presentation to the emergency room (148.8°), postreduction x-ray (157.3°), x-ray at 6 weeks at the time of presentation to our clinic (162.9°), x-ray at 10 weeks (166.7°), x-ray at 6 months (169°), x-ray at 1 year (174.7°), and x-ray at 2 years (175.7°).

extra-octave fracture of the little finger, and the remaining child had involvement of the ring finger. Fracture type was Salter-Harris II in 3 patients, JE I in 1 patient, and JE II in 4 patients. All x-rays at the time of injury were retrieved from the local hospitals, and the DHA in these x-rays ranged from 145.5° to 158.4° (mean of 150.3°). Immediate post–closed reduction x-rays were available in 6 cases, and in these, the DHAs ranged from 155.9° to 160.6° (mean of 157.8°). At the time of presentation to the author, 4 to 6 weeks after injury, the DHAs ranged from 156.4° to 162.9° (mean of 159.4°). Seven patients (patients 2–8 in Table 1) had normalization of the DHA (ie, an angle >177°) between 9 and 18 months. In the remaining patient (patient 1 in Table 1), the DHA was 175.7° at 2 years. The parents of this child were satisfied and never came back for further follow-up. Representative examples are shown in Figures 3–5.

DISCUSSION

Our series is unique with no similar series in the literature and shows that remodeling in the lateral plane occurs in pediatric fractures of the base of the proximal phalanx with DHA of 156° to 163°. Furthermore, the study shows that remodeling occurs with all fracture types. However, normalization of the DHA took 9 to 18 months in most cases. In 1 case, the DHA reached 175.7° at 2 years.

Malunion of fractures of the base of the proximal phalanx in children may occur in 3 different planes. Effective remodeling is known to

FIGURE 4. Case 3 (Table 1). A case of Salter-Harris II fracture. X-ray at time of presentation to the emergency room (145.5°). The fracture was reduced in the emergency room, but the postreduction x-ray was missing. X-ray at 6 weeks at the time of presentation to our clinic (156.5°), x-ray at 10 weeks (163.5°), x-ray at 6 months (169.4°), x-ray at 1 year (178.7°).

FIGURE 5. Case 5 (Table 1). A case of JE fracture type I. X-ray at the time of presentation to the emergency room (158.4°), postreduction x-ray (160.6°), x-ray at 5 weeks at the time of presentation to our clinic (161.9°). X-ray at 5 months (170.0°), x-ray at 8 months (173°), x-ray at 12 months (175.9°), x-ray at 18 months (178.0°).

occur for malunion in the flexion-extension plane. Remodeling for rotational deformities is much less effective. The effectiveness of remodeling in the lateral plane (ie, in radioulnar deformities) is known to be intermediate compared with the other 2 deformities.[4,8] Our study shows that remodeling in the lateral plane at the base of the proximal phalanx is more effective than previously thought.

Shewring[9] stressed on the fact that the decision to manipulate a child's finger with less than perfect reduction in proximal phalangeal base fractures remains clinical rather than radiological. At the time of presentation to our clinic, all fingers were deviated by clinical examination, and hence, further surgery was indicated. Shewring[9] also thought that the quantification of the residual angular deformity using the DHA would be useful in borderline cases in order to avoid the unnecessary interventions. We still recommend a second attempt of reduction if the postreduction x-ray shows a DHA of less than 170°. However, the main clinical message from our study is regarding late referrals (with no tenderness at the fracture site) with DHAs from 156° to 163°. In these cases, refracturing usually requires general anesthesia in these children. Our study shows that patients may be given the option of conservative management awaiting remodeling. The hand surgeon should also be aware that remodeling will occur not only in epiphyseal (Salter-Harris) fractures, but also in JE fractures, and there is no need for buddy taping of the fingers. However, intra-articular fractures are not considered because the reinstitution of the articular surface is the main aim of management. All the deviations of the extra-octave fractures are ulnar, but the same degree of remodeling would be expected if the deviation was radial. Finally, analysis of age and the degree of remodeling was not possible in the current study because of the relatively small number of patients. However, the openness of the epiphyseal plate is expected to be a factor in the remodeling potential.

REFERENCES

1. Al-Jasser FS, Mandil AM, Al-Nafissi AM, et al. Epidemiology of pediatric hand fractures presenting to a university hospital in Central Saudi Arabia. *Saudi Med J.* 2015;36:587–592.
2. Rajesh A, Basu AK, Vaidhyanath R, et al. Hand fractures: a study of their site and type in childhood. *Clin Radiol.* 2001;56:667–669.
3. Young K, Greenwood A, MacQuillan A, et al. Paediatric hand fractures. *J Hand Surg Eur.* 2013;38:898–902.
4. Fischer MD, McElfresh EC. Physeal and periphyseal injuries of the hand. Patterns of injury and results of treatment. *Hand Clin.* 1994;10:287–301.
5. Al-Qattan MM. Juxta-epiphyseal fractures of the base of the proximal phalanx of the fingers in children and adolescents. *J Hand Surg Br.* 2002;27:24–30.
6. Al-Qattan MM, Al-Motairi MI, Al-Naeem HA. The diaphysial axis–metacarpal head angle in the management of fractures of the base of the proximal phalanx in children. *J Hand Surg Eur Vol.* 2013;38:984–990.
7. Al-Qattan MM, Al-Zahrani K, Al-Boukai AA. The relative incidence of fractures at the base of the proximal phalanx of the fingers in children. *J Hand Surg Eur Vol.* 2008;33:465–468.
8. Barton NJ. Fractures of the phalanges of the hand in children. *Hand.* 1979;11:134–143.
9. Shewring D. Commentary on Al-Qattan et al. The diaphysial axis–metacarpal head angle in the management of fractures of the base of the proximal phalanx in children. *J Hand Surg Eur Vol.* 2013;38:991.